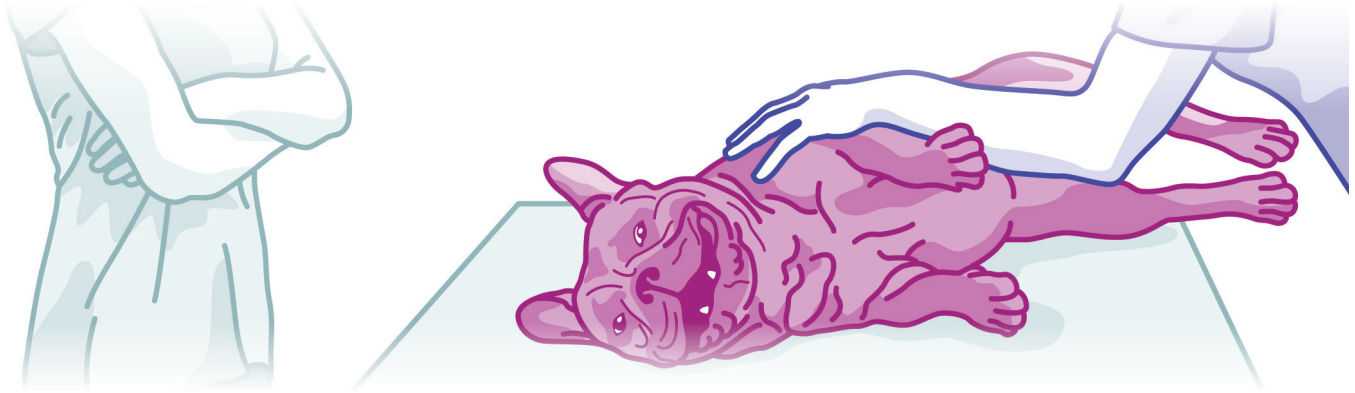

**CLAIM OF THE MONTH**

**SPINAL CORD COMPRESSION**

**Pet:** Lola,\* a 5-year-old female French Bulldog



**LOLA'S STORY:**

Lola wasn't part of just any family—she was part of the perfect family to watch over her health.

You see, she lived with a canine sister who had a history of herniated discs and spinal cord injury. So, when Lola started to show subtle signs of back leg incoordination and weakness, her humans knew right away they were dealing with a potentially serious problem.

In January, she started wobbling a bit while she walked. When veterinarians examined her, they could tell that the pup couldn't exactly tell where she was putting her feet down—a sign of spinal disease. Radiographs were performed, and they showed that Lola had a few "hemivertebrae": malformed bones in the spine that put unnatural pressure on the intervertebral discs. Her doctors suspected that a herniated disc might be pressing on the nerves in the spinal cord.

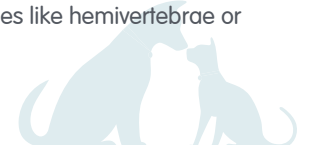Lola was given medication for pain and inflammation and strict orders to rest. She did well, with no apparent pain and only minor signs of ongoing incoordination.

In May, Lola started to have some fecal incontinence and worsening incoordination. She started to shuffle her back feet instead of lifting them normally. Although she still didn't show any signs of pain, her family took her back to the veterinarian for some more advanced imaging of the spine.

To everyone's surprise, the MRI showed that a fluid-filled cyst was compressing Monroe's spinal cord and causing her hind end problems. Like her sister, Lola also had some evidence of intervertebral disc disease, but the cyst was thought to be the primary problem.

**ABOUT THE CONDITION: ARACHNOID CYST AND SPINAL CORD COMPRESSION**

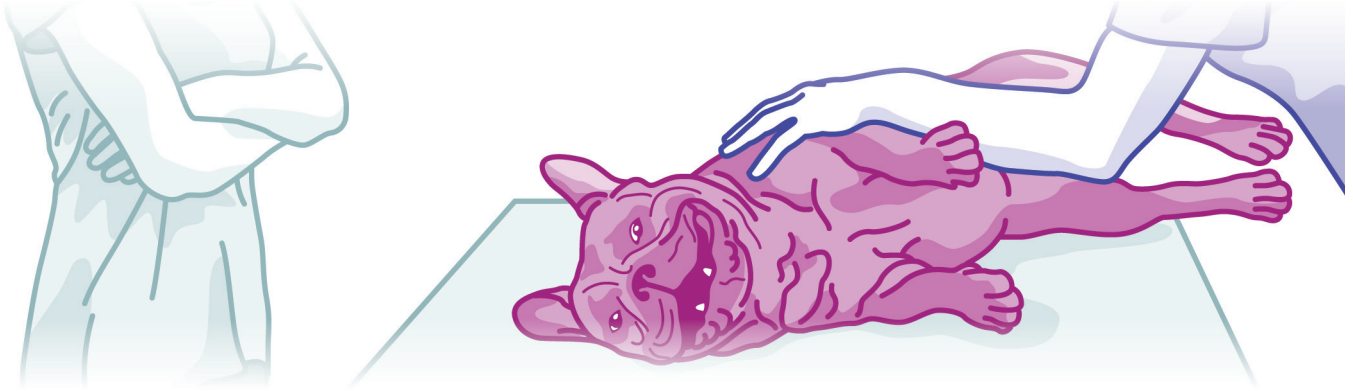
The brain and spinal cord are covered in protective membranes that separate the sensitive nerves from the rest of the body. A nutrient-rich liquid called cerebrospinal fluid (CSF) lubricates and cushions nervous tissue. In some cases, an abnormal pocket called an arachnoid cyst forms in the protective membrane. It becomes filled with CSF and takes up space in the spinal canal where nerves should freely course through. Over time, nerve compression can occur, and when this happens in the thoracic spine, it impairs the ability to sense and control the back limbs, tail, and anal sphincter. Some veterinarians believe spinal abnormalities like hemivertebrae or intervertebral disc degeneration can predispose a dog to develop arachnoid cysts.



## CLAIM OF THE MONTH

# SPINAL CORD COMPRESSION

Continued...



### TREATMENT

Treatment of arachnoid cysts involves removing part of the bone enclosing the spinal canal, and draining the fluid from the cyst. These two steps work together to reduce nerve compression in the area. A large incision is made in the cyst to prevent it from filling with fluid again. Damage to the compressed nerves may only be temporary, but permanent paralysis occurs for some dogs. Anti-inflammatory medications and a period of strict rest follow the surgery. Eventually, a slow build of rehabilitative exercises helps many dogs regain their strength, mobility, and sensation.

At this time, Lola is still resting. The next few weeks will be a very important time of rehabilitation as this family helps get their Frenchie back on her feet.

### CLAIM OUTCOME

Veterinary fees are sitting at around \$13,800 for treatment of Lola's spinal compression. Her Pets Plus Us Accident and Illness More plan has reimbursed her family the policy's annual maximum of \$7,500.00\*\*. We're rooting for your recovery, Lola!

Learn more about our Accident and Illness plan.

\*Details changed for privacy.

\*\*Sample claim for illustrative purposes - details have been changed for privacy. Based on 2023 PTZ Insurance Services Ltd. actual claims data. Dollar amounts have been rounded down.

